Concealed Neuroanatomy in Michelangelo's *Separation of Light From Darkness* in the Sistine Chapel

Ian Suk, BSc, BMC

Departments of Neurosurgery and Art as Applied to Medicine,
The Johns Hopkins University School of Medicine,
Baltimore, Maryland

Rafael J. Tamargo, MD, FACS

Department of Neurosurgery,
The Johns Hopkins University School of Medicine,
Baltimore, Maryland

Reprint requests:
Rafael J. Tamargo, MD, FACS,
Department of Neurosurgery,
Johns Hopkins Hospital,
600 North Wolfe Street,
Meyer Suite 8-181,
Baltimore, MD 21218.
E-mail: rtamarg@jhmi.edu

Received, February 16, 2009.
Accepted, December 2, 2009.

Copyright © 2010 by the Congress of Neurological Surgeons

Michelangelo Buonarroti (1475-1564) was a master anatomist as well as an artistic genius. He dissected cadavers numerous times and developed a profound understanding of human anatomy. From 1508 to 1512, Michelangelo painted the ceiling of the Sistine Chapel in Rome. His Sistine Chapel frescoes are considered one of the monumental achievements of Renaissance art. In the winter of 1511, Michelangelo entered the final stages of the Sistine Chapel project and painted 4 frescoes along the longitudinal apex of the vault, which completed a series of 9 central panels depicting scenes from the Book of Genesis. It is reported that Michelangelo concealed an image of the brain in the first of these last 4 panels, namely, the *Creation of Adam*. Here we present evidence that he concealed another neuronanatomic structure in the final panel of this series, the *Separation of Light From Darkness*, specifically a ventral view of the brainstem. The *Separation of Light From Darkness* is an important panel in the Sistine Chapel iconography because it depicts the beginning of Creation and is located directly above the altar. We propose that Michelangelo, a deeply religious man and an accomplished anatomist, intended to enhance the meaning of this iconographically critical panel and possibly document his anatomic accomplishments by concealing this sophisticated neuroanatomic rendering within the image of God.

KEY WORDS: Cadaver dissection, Michelangelo, Neuroanatomy, Sistine Chapel

Neurosurgery 66:851-861, 2010 DOI: 10.1227/01.NEU.0000368101.34523.E1 www.neurosurgery-online.com

In addition to being an artistic genius, the Florentine painter, sculptor, and architect Michelangelo Buonarroti (1475-1564) was a master anatomist. He acquired his vast understanding of human anatomy by performing cadaver dissections independently and in an unstructured fashion. Giorgio Vasari (1511-1574), Michelangelo's first biographer and contemporary, wrote in *Le vite de' più eccellenti pittori, scultori e architettori* (*The Lives of the Most Excellent Painters, Sculptors, and Architects*) (published in 1550 and expanded in 1568) that Michelangelo started to dissect cadavers when he was between 17 and 19 years old (in the period after the death of Lorenzo the Magnificent in 1492 and the expulsion of the Medicis from Florence in 1494).[1] According to Vasari, during this period, Michelangelo carved a wooden crucifix for Niccolo Bichiellini,[2] the prior of the church of Santo Spirito in Florence. The prior in return "provided him with spacious quarters, where on many occasions Michelangelo dissected dead bodies in order to study the details of anatomy and began to perfect the great skill in design that he subsequently possessed."[1] Ascanio Condivi (1525-1574), Michelangelo's student for many years and his second biographer, wrote in *Vita di Michelagnolo Buonarroti* (*Life of Michael Angelo Buonarroti*) (1553) that the artist had an intense interest in cadaver dissections and human anatomy:

> He had much familiar intercourse with the Prior [of the church of Santo Spirito], and received many kindnesses from him, among others the use of a room and subjects to enable him to study anatomy. Nothing could have given him more pleasure, and this was the beginning of his study of the science of anatomy, which he followed as long as fortune allowed him.[3]

Michelangelo performed cadaver dissections late into his life. According to both Vasari and Condivi, one of the foremost anatomists of the Renaissance, Matteo Realdo Colombo (1516-1559),

was a close acquaintance of Michelangelo's. Colombo became professor of Anatomy and Surgery in 1543 at the University of Padua, where he followed in this position Andries van Wesel (Andreas Vesalius, 1514-1564) and preceded Gabriele Fallopio (Fallopius) (1523-1562). From 1548 until his death in 1559, Colombo served as the first professor of Anatomy at the Sapienza, or Papal University, in Rome, and also was the surgeon to Pope Julius III (Giovanni Maria Ciocchi del Monte, 1487-1555).[4] Colombo hoped to publish an anatomic treatise with Michelangelo.[4] Condivi stated that at one point, Colombo even sent a corpse to Santa Agata for Michelangelo to dissect:

> He sent to Michelangelo for study the body of a Moor, a very fine young man, and very suitable for the purpose; he was sent to Santa Agata, where I then lived and still live, as it is a quiet place. On this corpse Michelangelo showed me many rare and recondite facts, perhaps never before understood, all of which I noted down, and hope one day, with the help of a learned man, to publish for the advantage and use of painters and sculptors . . . [3]

It is of interest that Colombo was Michelangelo's physician as well as close friend. Vasari described their relationship in this fashion:

> Michelangelo had a strong, healthy constitution, . . . as a man he only suffered two serious illnesses, and he always withstood every kind of hardship and had no ailments, except that in his old age he suffered from gravel in the urine which finally turned into kidney stones, and for many years he was in the hands of Master Realdo Colombo, his very close friend, who treated him with injections and looked after him carefully.[1]

We can only guess as to the depth of Michelangelo's anatomic knowledge because he did not publish any detailed drawings of his cadaver dissections. It is reported that he probably destroyed his numerous anatomic sketches and notes.[4] Only a few sketches of his anatomic studies have survived, and these are limited to depictions of musculoskeletal or topographic anatomy.[5] It is reasonable to assume, however, that given his genius and intense curiosity, Michelangelo probably became thoroughly familiar with the anatomy of the time, in the same fashion that he mastered the disciplines of painting, engineering, and architecture late in his career. Considering that Michelangelo was employed throughout his life primarily by the popes in Rome and that at the time, the church and the public viewed the dissections of corpses with ambivalence,[6,7] it is conceivable that Michelangelo might not have wanted to publicize this activity and thus jeopardize his position as artist for the Vatican.

We speculate that during his numerous dissections, Michelangelo possibly dissected the brain and spinal cord and that over the years he probably acquired a sophisticated understanding of gross neuroanatomy. It is difficult to conceive that during his dissections of cadavers, he would not have explored structures deep to the musculoskeletal system, in particular the brain. We know for a fact, however, that Leonardo da Vinci (1452-1519), one of Michelangelo's contemporaries and acquaintances, was also an accomplished dissector who documented his detailed understanding of the anatomy of the brain, spinal cord, and nerves in hundreds of drawings. Michelangelo might have been aware of Leonardo's neuroanatomic studies, given that they knew each other personally and, despite their animosity, studied each other's work carefully.[8] Alternatively, Michelangelo was probably familiar with neuroanatomic concepts that were spreading among anatomists in the early Renaissance. For instance, Mondino de Liuzzi's (1270-1326) *Anathomia* (written in 1316 but published in 1478)[9] was reprinted in Italian in 1493 as part of Johannes de Ketham's *Fasciculus Medicinae*, which was a compilation of different anatomic treatises.[10,11] Unlike Michelangelo, Leonardo produced an extensive corpus of anatomic drawings (>750).[12] Leonardo documented his detailed understanding of neuroanatomy in numerous illustrations.[13] As early as 1487, Leonardo illustrated the convergence of the optic nerves in the optic chiasm as a Y-shaped structure (Kenneth David Keele and Carlo Pedretti recto 4).[10] In about 1508, he correctly depicted the optic nerves/chiasm/tracts as an H-shaped structure (Keele and Pedretti recto 55).[11]

While in Florence during a continuous period of at least 2 years (1503-1505), Michelangelo came in contact with Leonardo repeatedly before Michelangelo's return to Rome in 1505. During this period, Michelangelo might have become aware of Leonardo's anatomic illustrations, which dated back to 1487. Michelangelo was already in Florence in the spring of 1503 working on the *David* when Leonardo returned to this city and received the commission from the Gonfaloniere of Justice of Florence, Piero Soderini, to paint a fresco of the *Battle of Anghiari* on one wall of the Grand Hall of the Council (Salone dei Cinquecento) in the famous Palazzo della Signoria (now known as the Palazzo Vecchio).[1,8] The following year (1504), soon after completing the *David*, Michelangelo was commissioned to paint the *Battle of Cascina* on the opposite wall of the Grand Hall.[14] Therefore, the 2 artists were in Florence continuously for 2 years, from the spring of 1503 until February 1505, at which time Michelangelo was summoned to Rome by Pope Julius II (Giuliano della Rovere, 1443-1513) to start work on the Pope's tomb. Leonardo was officially excused from his commission in Florence a year later on May 30, 1506.[15] Incidentally, neither fresco was ever completed. Michelangelo finished and displayed the full-size sketch of the fresco, but never started the painting. Leonardo completed his sketch, started the fresco, but abandoned it after he "created a composition so thick for the coating of the walls that while he continued to paint in the hall, it began to run, so that he soon abandoned the work, seeing that it was ruined."[1] When Michelangelo left for Rome in February 1505, he might have already been exposed to Leonardo's neuroanatomic drawings.

On May 10, 1508, Michelangelo began preparations to paint the vault of the Sistine Chapel, as commissioned by Pope Julius II.[2] Condivi wrote that Michelangelo started to paint the Sistine Chapel ceiling from the entrance of the chapel and proceeded toward the altar, from east to west.[3] Along the longitudinal apex of the ceiling,

Michelangelo painted 9 central panels (5 small panels alternating with 4 large panels) that depict scenes from the Book of Genesis. The chronological story of these 9 panels (from the creation of the world through the story of Adam and Eve to the story of Noah) unfolds from the far end of the chapel, where the altar is located, toward the entrance, but Michelangelo painted them in the opposite direction and in reverse chronology, from entrance to altar.

The last 4 panels along the longitudinal axis of the vault (*Creation of Adam* (Genesis 1: 26-27), *Separation of Land and Waters* (Genesis 1: 9-10), *Creation of the Sun and Moon* (Genesis 1: 14-19), and *Separation of Light From Darkness* (Genesis 1: 3-5) are clearly stylistically different from the first 5. Indeed, they were painted as a separate series over a period of about a year (Figure 1A-D). God is the central figure in these 4 panels and is depicted as robust and dynamic, but in muted colors. These last 4 panels, which Michelangelo started to paint in the winter of 1511 after a hiatus of at least 6 months,[14,16] are thematically and esthetically simpler; whereas the first 5 panels are more narrative and each involve several characters, the last 4 emphasize just God and either Adam or the elements.

The final and ninth central panel, the *Separation of Light From Darkness* (Figure 1), was probably completed in the summer of the following year, 4 months before the Sistine Chapel was reopened to the public on November 1, 1512 (All Saints' Day).[17] King[14] writes that Michelangelo had just finished the last 2 scenes of Genesis, the *Creation of the Sun and Moon* and *Separation of Light From Darkness*, shortly before Alfonso d'Este, the Duke of Ferrara (1476-1534), visited the Vatican in July 1512 and asked to see

FIGURE 1. *The last 4 panels painted by Michelangelo along the longitudinal axis of the Sistine vault are the* Creation of Adam *(Genesis 1: 26–27) (**A**),* Separation of Land and Waters *(Genesis 1: 9–10) (**B**),* Creation of the Sun and Moon *(Genesis 1: 14–19) (**C**), and the* Separation of Light From Darkness *(Genesis 1: 3–5) (**D**). The* Separation of Light From Darkness *was one of the last Sistine Chapel frescoes painted by Michelangelo. It depicts the first act performed by God in the creation of the universe (Genesis 1: 3–5). This final panel has a special location in the Sistine Chapel because it is situated directly above the altar.*

Michelangelo's work in progress. The *Separation of Light From Darkness* has a special location in the Sistine Chapel because it is situated directly above the altar. It is reported that Michelangelo painted it in one *giornata*, ie, a single working day of approximately 8 hours, based on analyses of its surface.[14,18] In this panel, he uses the challenging ceiling painting technique of *sotto in sù* (from below upward), which creates the illusion of a figure rising into the sky above the viewer by using extreme foreshortening.[18] Vasari described this panel as representative of Michelangelo's ability at his peak:

> Furthermore, to demonstrate the perfection of his art and the greatness of God, Michelangelo depicted God dividing the light from the darkness in these scenes, where he is seen in all his majesty as He sustains Himself alone with open arms with the demonstration of love and creative energy.[1]

In a provocative article published in 1990, Meshberger[19] made the surprising but cogent argument that in the *Creation of Adam* (the first and arguably the most famous of the final 4 panels), Michelangelo illustrated a human brain (Figure 2). Over time, Meshberger's argument has gained the cautious support of art scholars. For instance, Salcman,[20] an expert in both art history and neuroanatomy, states that Meshberger's interpretation is supported by Michelangelo's Platonic philosophical inclinations and by his cadaver dissections, but he also cautions that "our visual systems . . . fill in details and create meaning where no pattern or meaning may have been intended." Meshberger speculates that Michelangelo surrounded God with a shroud representing the brain to suggest that God was endowing Adam not only with life, but also with intelligence. This shroud, he proposed, has the shape of the cerebrum with composite features of both midsagittal and lateral views of the brain (Figure 2). In Figure 2, we synthesize Meshberger's thesis pic-

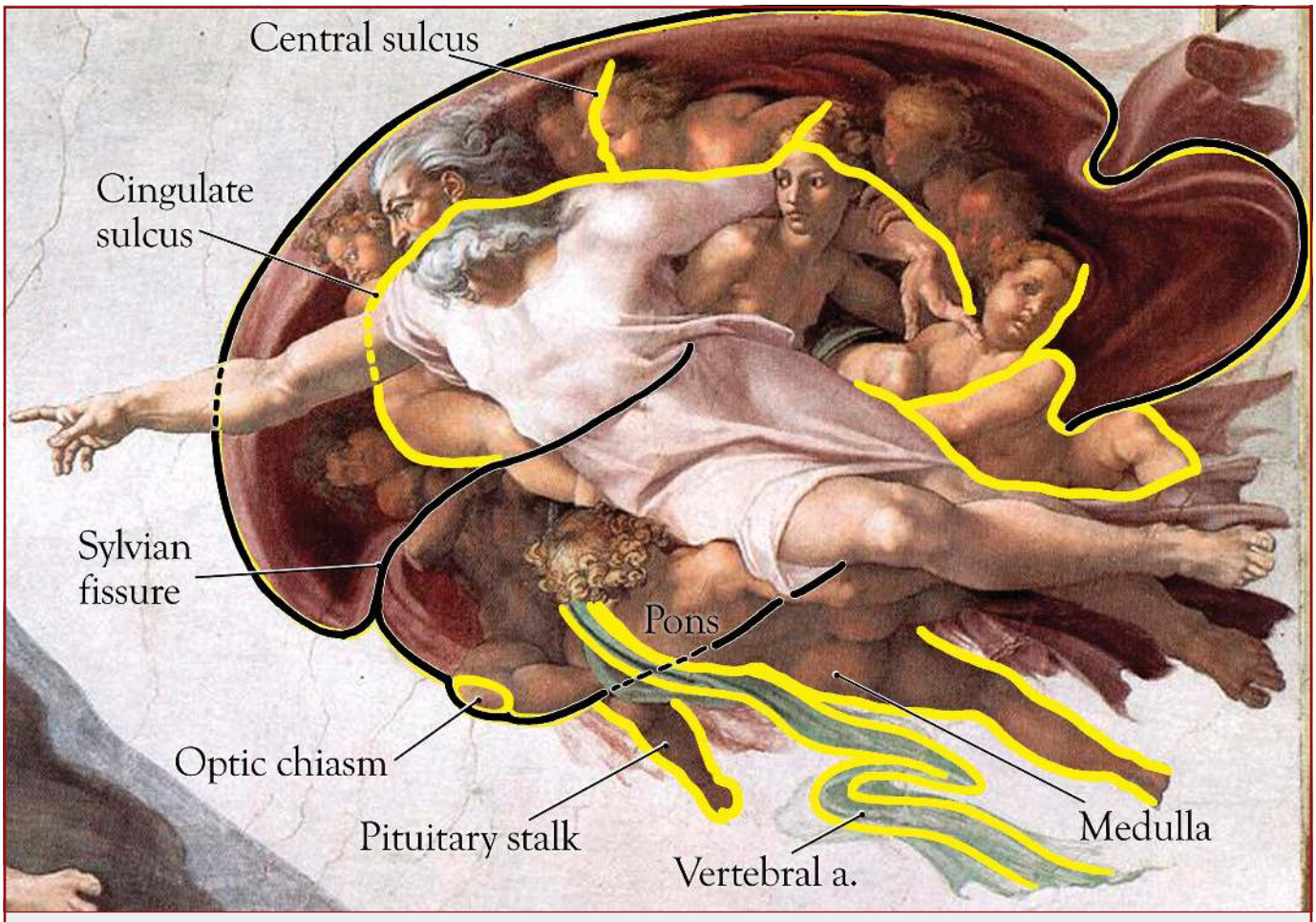

FIGURE 2. *Composite view of F. L. Meshberger's[19] pictorial thesis regarding the embedded image of the brain in the* Creation of Adam*, which contains anatomic features of the midsagittal and lateral surfaces of the brain. The optic chiasm and tract are depicted by the right thigh and leg of the first angel below God, the pituitary stalk and gland by the left leg and foot of the same angel, the pons by the torso of the second angel below God, the medulla and cervical spinal cord by the thigh and leg of this second angel, and the basilar and vertebral arteries by a flowing sash below this angel; the cingulate sulcus is suggested by the contours of the hip of the angel in front of God, God's shoulders, and God's extended left arm and the sylvian fissure (a lateral landmark) by an indentation in the anterior aspect of the robe, the angel's right arm, and God's waist. The green sash resembles the basilar and vertebral arteries. A midsagittal section of the optic chiasm is apparent. a., artery.*

torially by outlining and superimposing the anatomic landmarks of the midsagittal and lateral surfaces of the brain. If one accepts Meshberger's interpretation, one must conclude that Michelangelo had a profound understanding of the anatomy of the brain.

It is of interest that these last 4 central panels may have an underlying anatomic motif. Eknoyan[16] suggested that in the *Separation of Land and Waters*, Michelangelo embedded the image of a bisected right kidney in the mantle around God. Michelangelo had a personal interest in the kidney and urinary function as he suffered from nephrolithiasis most of his life. He documented an interest in the kidney in his correspondence, poetry, and drawings.[16] Eknoyan also shows that, in addition to the shroud enveloping God, in this panel the naked figure (*ignudo*) above the Persian Sybil, whose back is turned to the observer, is flanked by 2 embedded images of the kidneys.

Given that Michelangelo linked God with the brain in the *Creation of Adam*, we hypothesized that he might have concealed images of the brain in other depictions of God within this set of 4 panels. Not surprisingly, we then found another even more sophisticated neuroanatomic illustration embedded in the image of God in the *Separation of Light From Darkness*. For the purpose of our argument, it is of particular significance that, based on his depiction of the brain in the *Creation of Adam*, Michelangelo was familiar with the anatomy of the pituitary region, the pons, and medulla.

The *Separation of Light From Darkness* is an important panel in the iconography of Michelangelo's Sistine Chapel ceiling. It depicts the first act performed by God in the creation of the universe. It is situated immediately above the altar in the chapel. As described previously, Vasari stated that Michelangelo rendered this panel to "demonstrate the perfection of his art and the greatness of God."[1] Considering Michelangelo painted the *Separation of Light From Darkness* at the end of the Sistine Chapel project and that he intended to portray God in all His glory, it is intriguing that this painting has prominent "irregularities" that have mystified observers and scholars for centuries. These irregularities are found in God's neck, which has several details that are not anatomically accurate, and in the apparently discordant light source in this fresco. Are these irregularities simply rendering accidents? We propose that they are not. Alternatively, did Michelangelo, at the peak of his abilities, intend to portray something else? We submit that he did.

We propose that in the *Separation of Light From Darkness*, Michelangelo drew into God's neck a ventral view of the brainstem as well as the perisellar and chiasmatic regions. A comparison of God's neck in the *Separation of Light From Darkness* with those of other Sistine Chapel figures in the same three-quarter turn view, as well as those from contemporary paintings by either Leonardo or Raffaello Sanzio (Raphael) (1483-1520), demonstrates that Michelangelo drew a more complex structure into God's neck (Figure 3).



FIGURE 3. *Comparative anterolateral oblique views of the human neck depicted by Michelangelo throughout the Sistine Chapel ceiling, by Leonardo da Vinci, and by Raffaello Sanzio (Raphael). Some figures are reversed to match the orientation of God's head in the* Separation of Light From Darkness. **A**, *Adam (reversed), from the* Creation of Adam. **B**, *Ignudo, from the* Sacrifice of Noah. **C**, *Adam (reversed), from the* Expulsion From the Garden of Eden. **D**, *Eve (reversed), from the* Expulsion From the Garden of Eden. **E**, *Virgin Mary (reversed), from* The Virgin and Child With St. Anne *(ca. 1508) by Leonardo da Vinci.* **F**, *Virgin Mary, from* Holy Family Below the Oak *(1518) by Raffaello Sanzio (Raphael).* **G**, *God, from the* Separation of Light From Darkness. *Note the difference between the normal neck anatomy depicted in* **A-F** *compared with that of God's neck in* **G**.

To depict the human neck in this perspective, Michelangelo characteristically drew the anterior border of the stretched sternocleidomastoid muscle and depicted along the midline 2 smooth prominences (namely, the thyroid cartilage superiorly and the cricoid cartilage and trachea inferiorly). In the *Separation of Light From Darkness*, there are instead 4 prominences along the midline, 2 superior paramedian prominences on the left and 1 on the right, and no suprasternal fossa (Figure 4A). Furthermore, the third prominence (from the top) has a midline cleavage. The anterior border of the sternocleidomastoid muscle is indistinct. Moreover, God's beard, which is typically depicted by Michelangelo in the other 3 panels as long and flowing, in this foreshortened view has been excessively "rolled up" and has a midline depression and 2 lateral, round bulges. We submit that Michelangelo drew a ventral brainstem into God's neck and that the 4 midline prominences are (from inferior to superior) the upper cervical spinal cord, the medulla (which is divided by its midline sulcus), the pons, and the sellar region. The 2 superior paramedian prominences on the subject's left are the anterior bulge of the cerebellar hemisphere and the cerebellar flocculus. The central depression in the beard is the subfrontal interhemsipheric fissure, and the lateral bulges are the subfrontal regions bounded medially by the olfactory tracts (Figure 4C). Stunningly, following Michelangelo's outline, one can draw into God's neck and beard an anatomically correct ventral depiction of the brain (Figure 4C).

Another irregularity in this fresco is that God's neck has a light source different from that of the rest of the painting (Figure 5). Michelangelo was a master at depicting light accurately. The *Separation of Light From Darkness* is illuminated diagonally from the lower left portion of the frame (Figure 5A). God's neck, however, is illuminated head on and slightly from the right, thus "highlighting" the neck (Figure 5B). It is unlikely that this feature is accidental. We propose that Michelangelo intended to highlight his depiction of the ventral brainstem using the additional light source.

Furthermore, a digital "shadow analysis" of the neck yields "structures" that happen to correspond, in modern neuroanatomic terminology, to the basal cisterns around the brainstem (Figures 6 and 7). Obviously, it is unlikely that Michelangelo recognized the presence of the arachnoid cisterns as anatomic structures framing the brainstem structures. The cisterns were first described in detail in 1875 by the Swedish anatomists Axel Key (1832-1901) and Gustaf Retzius

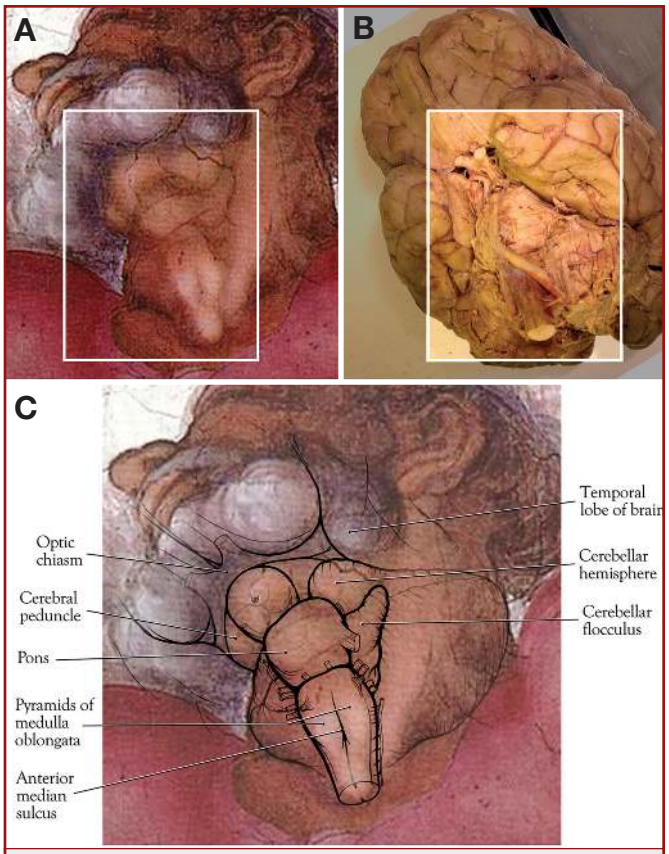

FIGURE 4. *Comparative views of brainstem landmarks in the* Separation of Light From Darkness. *Brainstem anatomy in the highlighted box by Michelangelo (**A**) is compared with a similar area outlined in a cadaver dissection (**B**). **C**, the overlay showing the specific midbrain structures that correspond to the unusual features in God's neck as depicted by Michelangelo.*

FIGURE 5. *Analysis of 2 disparate light sources in the* Separation of Light From Darkness. **A**, *the overall light source illuminating God emanates diagonally from the lower left of the frame (arrow).* **B**, *Inset (gray scale, increased contrast): God's neck is illuminated mainly head on and slightly from the right. This notable irregularity is not consistent with Michelangelo's otherwise masterful depiction of light on form and is unlikely to be accidental.*

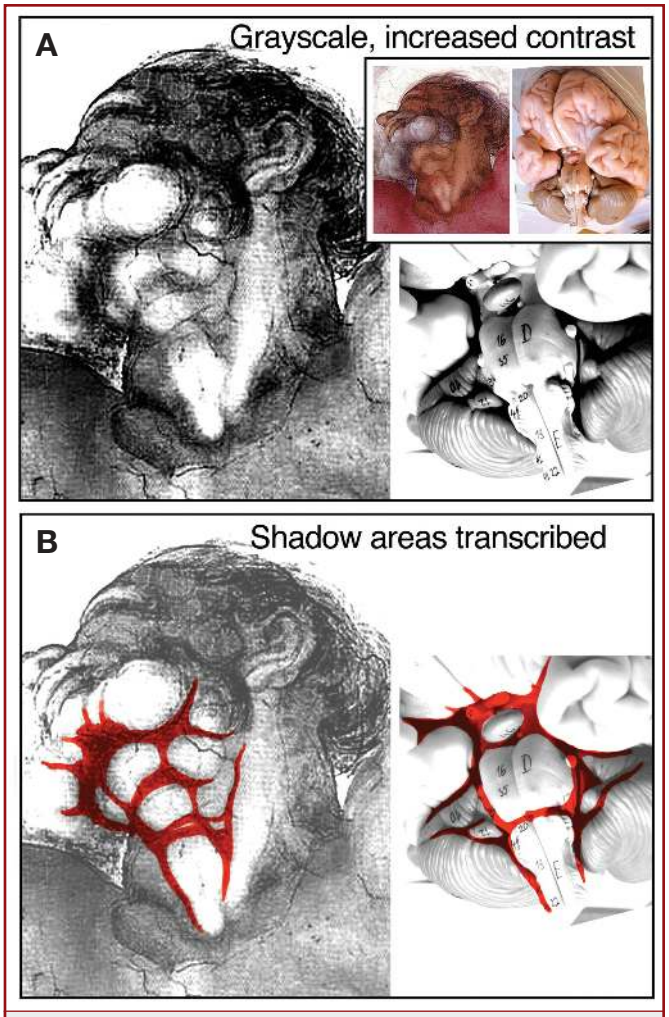

FIGURE 6. *Digital "shadow analysis."* **A**, *close-up of God's neck (gray scale, increased contrast) is compared with a photograph of a plastic brain model (SOMSO-plast Brain model BS20, 2001) in similar oblique, ventral views. Inset shows original color photo for context.* **B**, *shadow areas are transcribed in red using a digital paintbrush in Adobe Photoshop (CS2, 2005).*

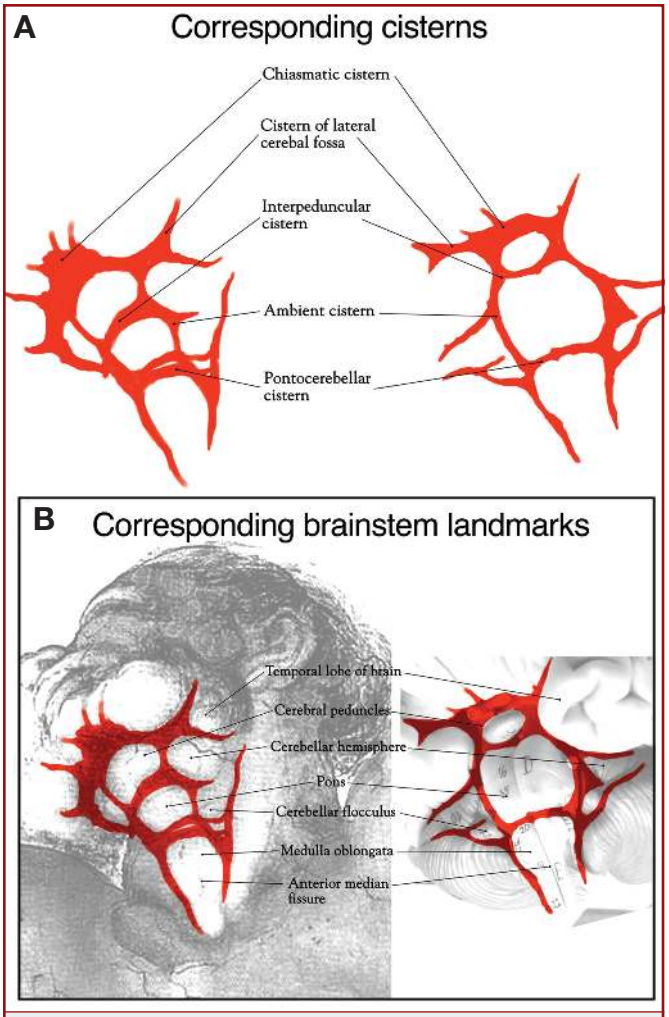

FIGURE 7. *Comparison of the shadow outline of God's neck in the* Separation of Light From Darkness *with the anatomy of the basal cisterns.* **A**, *when the reference gray-scale images are removed, the red shadow areas correspond precisely to the anatomy of the basal cisterns.* **B**, *the negative spaces between the cisterns correspond to the characteristic brainstem landmarks.*

(1842-19191), who used histological dyes and microscopic magnification for this purpose.[21,22] Nevertheless, Michelangelo, like all painters, depicted form by applying brushstrokes to render light and dark areas and had the ability to do so with almost photographic accuracy. Not surprisingly then, the dark areas in God's neck correspond precisely to the anatomy of the basal cisterns (Figure 7).

Why did Michelangelo depict a ventral view of the brainstem in the *Separation of Light From Darkness*? We speculate that having used the brain motif successfully in the *Creation of Adam* almost a year earlier, Michelangelo wanted to once again associate the figure of God with a brain in the iconographically critical *Separation of Light From Darkness*. Given that the brainstem is a conical structure, Michelangelo concealed it in the anterior space of the neck, which has a similar configuration. In addition it places the brainstem close to its anatomic position, if one could see it through the neck structures. This is a strikingly sophisticated "phantom view" of the ventral brain, but one that would not have been beyond the talent of an artistic genius who also happened to be a master anatomist. This oblique, ventral perspective displays not only Michelangelo's anatomic expertise but also appears to build upon his earlier accomplishment of depicting a more straightforward midsagittal view of the brain in the *Creation of Adam*.

God's neck in the *Separation of Light From Darkness* has previously drawn the attention of others who suggested Michelangelo intended to depict a goiter.[23] We disagree with this interpretation based on 2 points. The first is that if Michelangelo wanted to depict a goiter, he would have been able to draw a more anatomically accurate lesion. He had the opportunity to observe this condition closely in the people of the Po River valley in Lombardy, where goiter was endemic. The structure in the neck simply does not look like a

hypertrophied thyroid gland. The second point is that it is unlikely that Michelangelo, a deeply religious individual, would have defiled the image of God in this important panel by giving God a goiter.

At the risk of stretching our neuroanatomic interpretation of this fresco too far, we point out that there could be 2 other neuroanatomic structures hidden in God's torso. We recognize, however, that the pictorial evidence in favor of these 2 other structures is not as robust as that associated with the ventral brainstem. An examination of God's torso reveals in the midline a peculiar tubular structure with a longitudinal cleft. In the last 4 panels, which Michelangelo



FIGURE 8. *Midline irregular structure with a longitudinal cleft in God's robe (arrow) in the* Separation of Light From Darkness. *This midline structure is not present in the previous 3 depictions of God in this set of 4 panels (note that the right paramedian line in* **B** *is an extension of a crack in the Sistine Chapel ceiling).* **A**, Creation of Adam. **B**, Separation of Land and Waters. **C**, Creation of the Sun and Moon. **D**, Separation of Light From Darkness.

painted as a collective series between the winter of 1511 and the summer of 1512, Michelangelo dressed God in essentially the same red robe (Figure 8). Interestingly, this midline seam or fold on God's chest is not present in the first 3 panels (*Creation of Adam*, *Separation of Land and Waters*, and *Creation of the Sun and Moon*). Furthermore, this seam or fold does not flow accurately within the fabric of the robe, nor does it follow God's torso, which turns in a *contrapposto* pose. Michelangelo was masterfully adept at the realistic rendering of folds in the clothing of his subjects, and this anomaly seems to be a departure from his other fabric renderings. Is this structure, a similarly oblique, ventral view of the cervicothoracic spinal cord, which is depicted as an offset continuation of the inferior medulla in God's neck (Figure 9)? Finally, below God's waist, there is a peculiar Y-shaped structure that appears to be out of place and does not blend with other folds in God's robe. Could this structure be an allusion to the optic chiasm and the optic nerves (Figure 10)? As we described earlier, Leonardo illustrated the optic apparatus as a Y-shaped structure as early as 1487,[10] 21 years before Michelangelo started to paint the Sistine Chapel ceiling. As they cross under God's sash, the optic nerves appear to give rise to bilateral, subtle globular masses in God's subcostal regions, possibly representations of the optic globes. Although there is no record of Michelangelo's dissections of the optic chiasm, optic nerves, and orbits, it is likely that Michelangelo was aware of contemporary depictions of the optic apparatus by either Leonardo or other Renaissance anatomists. Michelangelo could have been particularly interested in including the organs of vision and its neural structures in the *Separation of Light From Darkness*.

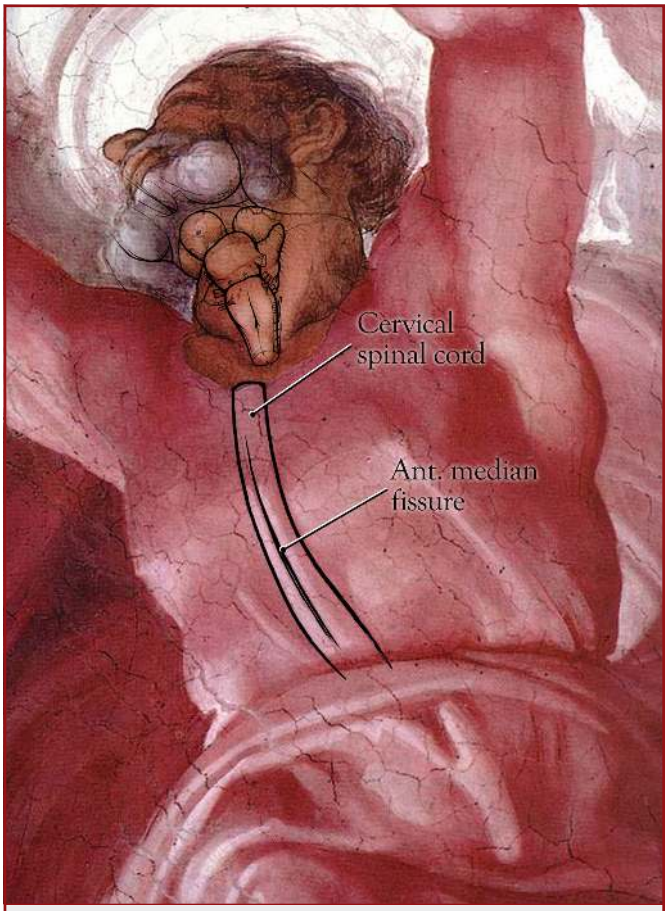

FIGURE 9. *Concealed ventral view of the brainstem and the cervicothoracic spinal cord in the* Separation of Light From Darkness. *Ant., anterior.*

Although we recognize the perils of overinterpreting a masterpiece like Michelangelo's *Separation of Light From Darkness*, we submit that the anatomic incongruities in this fresco are not accidental and warrant an explanation. Meshberger's[19] assertion that Michelangelo incorporated a view of the brain in the *Creation of Adam* is compelling and appears to be gaining support among art historians. In art history, there are few opinions that stand undisputed, and most are sustained by either circumstantial evidence or simply by the cumulative analyses of observers, because artists do not issue their works with an explanatory text. It is unquestionable that Michelangelo performed cadaver dissections and that he had an intense fascination with human anatomy. It follows that, like Leonardo, Michelangelo probably explored gross neuroanatomy and developed an understanding of the brain's important function. Being a painter of genius, a master anatomist, and a deeply religious man, Michelangelo cleverly enhanced his depiction of God in the iconographically critical panels on the Sistine Chapel vault with concealed images of the brain and in this way celebrated not only the glory of God, but also that of His most magnificent creation.

Disclosure

The authors have no personal financial or institutional interest in any of the drugs, materials, or devices described in this article.

REFERENCES

1. Vasari G, Bondanella JC, Bondanella PE. *The Lives of the Artists*. Oxford, England; New York, NY: Oxford University Press, Inc.; 1550/1998.
2. Bull G. *Michelangelo: A Biography*. New York, NY: St. Martin's Press; 1995.
3. Condivi A, Holroyd C. *The Life of Michael Angelo Buonarroti*. Elibron Classics ed. London, England; New York, NY: Duckworth and Co.; Charles Scribner's Sons; 1553/1903.
4. Eknoyan G, De Santo NG. Realdo Colombo (1516-1559). A reappraisal. *Am J Nephrol.* 1997;17(3-4):261-268.
5. Elkins J. Michelangelo and the human form: his knowledge and use of anatomy. *Art Hist.* 1984;7(2):176-186.
6. Brown EA. Death and the human body in the later Middle Ages: the legislation of Boniface VIII on the division of the corpse. *Viator.* 1981;12:221-270.
7. Park K. The criminal and the saintly body: autopsy and dissection in Renaissance Italy. *Renaissance Quarterly.* 1994;47(1):1-33.
8. Wilde J. Michelangelo and Leonardo. *Burlington Magazine.* 1953;95:65-77.
9. Rengachary SS, Cohen C, Dass K, Guthikonda M. Development of anatomic science in the late middle ages: the roles played by Mondino de Liuzzi and Guido da Vigevano. *Neurosurgery.* 2009;65:787-794.
10. Del Maestro RF. Leonardo da Vinci: the search for the soul. *J Neurosurg.* 1998; 89(5):874-887.
11. Clayton M, Philo R. *Leonardo da Vinci: The Anatomy of Man. Drawings From the Collection of Her Majesty Queen Elizabeth II*. Boston, MA: Bulfinch Press; 1992.
12. Choulant L, Frank M. *History and Bibliography of Anatomic Illustration in Its Relation to Anatomic Science and the Graphic Arts*. Chicago, IL: University of Chicago Press; 1852/1930.
13. Casson H. Leonardo da Vinci. *Anatomical Drawings From the Royal Collection*. London, England: Curwen Press; The Royal Academy of Arts; 1977.
14. King R. *Michelangelo and the Pope's Ceiling*. New York, NY: Penguin Books; 2003.

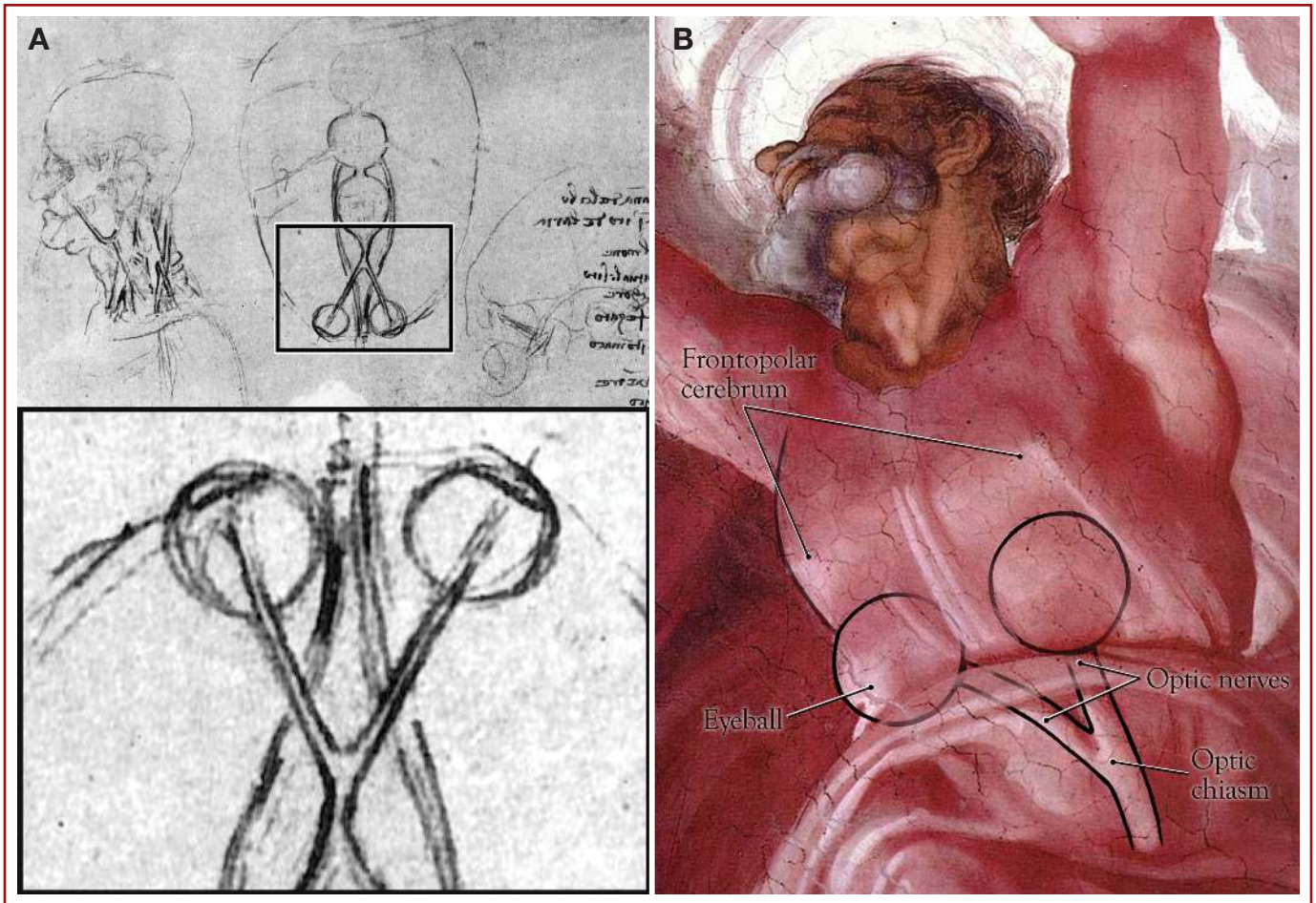

FIGURE 10. A, *drawing by Leonardo da Vinci ca. 1487 depicting the optic nerves overlying the globes and converging on the optic chiasm as a Y-shaped structure (Kenneth David Keele and Carlo Pedretti recto 4 in the Royal Collection of Her Majesty Queen Elizabeth II).*[11] *Michelangelo, who last came in close contact with Leonardo in Florence from 1503 to 1505 before starting to paint the Sistine Chapel in 1508, probably envisioned the optic apparatus as a Y-shaped structure.* **B**, *concealed view of the optic chiasm, optic nerves, and globes in* Separation of Light From Darkness.

15. Farago CJ. Leonardo's Battle of Anghiari: A study in the exchange between theory and practice. *Art Bulletin.* 1994;76(2):301-330.
16. Eknoyan G. Michelangelo: art, anatomy, and the kidney. *Kidney Int.* 2000;57(3):1190-1201.
17. Cast D. Finishing the Sistine. *Art Bulletin.* 1991;73(4):669-684.
18. Graham-Dixon A. *Michelangelo and the Sistine Chapel*. London, England: The Orion Publishing Group Ltd.; 2008.
19. Meshberger FL. An interpretation of Michelangelo's Creation of Adam based on neuroanatomy. *JAMA.* 1990;264(14):1837-1841.
20. Salcman M. The Creation of Adam by Michelangelo Buonarroti (1475-1564). *Neurosurgery.* 2006;59(6):N11-N12.
21. Yaşargil MG. *Microneurosurgery.* Vol 1. Stuttgart, Germany; New York, NY: Georg Thieme Verlag; Thieme Medical Publishers; 1987;
22. Bakay L. Discovery of the arachnoid membrane. *Surg Neurol.* 1991;36(1):63-68.
23. Bondeson L, Bondeson AG. Michelangelo's divine goitre. *J R Soc Med.* 2003;96(12):609-611.

Acknowledgments

This work was supported in part by a generous gift from the Rosenberg Family to R.J.T. and by the Walter E. Dandy endowment to R.J.T. The authors thank Dr Ziya Gokaslan for his review and suggestions.

COMMENTS

It is a pleasure to have the opportunity to comment on this beautiful and provocative article. It is important for the authors to consider whether they have not taken their argument a bit too far. Although I do not have the advantage of seeing their original computer-generated analysis, I am concerned about adding the spinal cord speculation and, even more so, the optic chiasm speculation, to the nicely demonstrated inscription of the ventral brainstem in the throat of God. In the latter case, they have the supporting evidence of the change in the direction of the illumination as well as many details of the structure nicely outlined. In 1 anatomic instance, however, they may have erred; even by their own dissection specimen in Figure 4, Michelangelo would not have drawn the cerebellar hemisphere as superior to the pons but largely lateral to it. I do not believe that their identification of the cerebellum in the finished painting is correct. Furthermore, they have partially misrepresented what I hoped was the nuanced view presented in my article.[1] I am not an unabashed admirer of Meshberger's conclusions. Although I accept the hypothesis as plausible, I also point out the neurophysiological tendency

of the brain to fill in or complete partial visual information so as to make sense of the world, and I quote the eminent abstract expressionist painter Willem de Kooning in regard to the principle that there is no painting so abstract that it will not contain a resemblance. In support of this caution, I would remind the reader that nephrologists tend to see kidneys in the Sistine Chapel paintings, whereas neuroscientists tend to see brains.

It is not established that Michelangelo did dissections throughout his life, certainly not to the degree that Leonardo did, and it would have been very dangerous for him to do so while in the direct employ of the Pope. Incidentally, the wooden crucifix that the 18-year-old Michelangelo carved in 1493, partially based on his early dissections, was only rediscovered in 1962 and finally returned to the Santo Spirito Church in Florence after authentication in 2000[2]; the attribution is still a matter of debate. It is pure speculation that Leonardo would have shown his anatomic drawings to his younger competitor. There is no evidence to suggest that the 2 artists made reciprocal studio visits on a regular basis in the manner of Matisse and Picasso.[3,4] Nevertheless, the description of Michelangelo's relationships with his friends and his physician are outstanding. My congratulations to the authors on their analysis of the hidden inscription of neuroanatomy in the Sistine Chapel paintings; Suk and Tamargo have performed the most detailed and technologically sophisticated analysis of this issue ever presented. As they so carefully indicate, some issues in art history can never be fully adjudicated. Despite the uncertainty involved, the complexity of such intellectual speculation would have surely pleased Leonardo and Michelangelo, 2 men who embodied the ideal of a continuing dialogue between art and science.

Michael Salcman
Baltimore, Maryland

1. Salcman M. The Creation of Adam by Michelangelo Buonarroti (1475-1564). *Neurosurgery*. 2006;59:N11-12.
2. Crucifix 'confirmed' as a Michelangelo. http://news.bbc.co.uk/2/hi/entertainment/1444780.stm. Accessed September 30, 2009.
3. Canaday J. *The Lives of the Painters*. Vol 1. New York, NY: Norton; 1969:189-226.
4. de Wald ET. *Italian Painting*, 1200-1600. New York, NY: Holt Rinehart Winston; 1961:353-396.

The Sistine Chapel has been clearly documented as one of Michelangelo's great accomplishments. Over the years, there have been many papers and chapters written both on the artist and his paintings and sculptures. In this article, we are reading the views of an anatomic illustrator and a neurosurgeon's "look" at the Sistine Chapel and seeing a previously unrecognized neuroanatomy in the figure of God in the panel *Separation of Light From Darkness*. The authors begin with a historical introduction of Michelangelo and his lifelong interest in human anatomic dissection. They then carefully analyze the anatomic form of this panel and are able to locate an outline of the brain, the ventral brainstem, and its vascular anatomy along with a proposed outline of the anterior portion of the cervicothoracic spinal cord. The authors also postulate the optic nerves and chiasms can also be seen in outline of the robes of God. In the illustrations, they provide the reader with the schematics overlying the painting so that we can easily appreciate the anatomy. This article is a clearly a clever and unique contribution to neurosurgery and neuroanatomy.

James Tait Goodrich
Bronx, New York

God definitely seems to be inside a sagittal contour of the brain in the *Creation of Adam* panel of the Sistine Chapel, suggesting to be providing man also with intelligence, as perceived and described by Meshberger in 1990.[1] Considering that Michelangelo suffered from nephrolithiasis, it is also very probable that he painted God within a kidney shape in the Sistine Chapel's *Separation of Land and Waters* panel, as suggested by Eknoyan[2] in 2000 and as pointed out by Suk and Tamargo in this article. God's neck and torso also seem to disclose particularly the brainstem and the spinal cord, as his axis, in the *Separation of Light From Darkness* panel. In addition to this interesting contribution, Suk and Tamargo also provide us with a very comprehensive description of the inherent art and anatomic relationships that were so deeply explored in the Renaissance, particularly by Michelangelo and Leonardo da Vinci.

Looking at the same subject, Barreto and Oliveira[3] published in 2004 in Brazil a whole book about further anatomic findings in Michelangelo's masterpieces, and it is interesting to observe that in the same figure of God painted in *Separation of Light From Darkness* panel in the Sistine Chapel, they recognized the image of a hyoid bone, with its U-shaped format given by God's elevated arms.

In the same direction, it is interesting and also appropriate to recall that one of the main features of the fractal geometry described by Mandelbrot[4,5] in the 1960s is the self-similarity that can be observed along the so-called fractal scaling, which indicates that as viewers peer more deeply into the fractal images of chaotic systems, they notice that the shapes seen at one scale are similar to the shapes seen in the details at another scale.[6]

Forms and shapes are then very important expressions of our universe in very different dimensions, and parallel to their beauty, their similarities throughout these different dimensions are intriguing, and the understanding of their meanings is still attributed to many elements. Forms and shapes in Nature should have a reason and a purpose. Regarding the central nervous system, we already know that they are, at least partially, attributable to the folding and bending processes that took place along evolution to allow an increase in its surface and complexity without a proportional increase in its volume,[7] but we do not yet know the full meaning of its architecture or of the intrinsic relationships that the forms and shapes of its structures might have with its physiology. Siler,[8] in a very provocative book, speculates about these relationships, pointing out similarities between shapes of brain structures and telescopic images of the cosmos and between the shapes of neural structure and of electromagnetic fields reactors.

It is hoped that science will continue to pursue these answers and art will continue to express the clear and the concealed beauties of our universe, as well shown by Suk and Tamargo through the excellence of Michelangelo Buonarotti.

Guilherme Carvalhal Ribas
São Paulo, Brazil

1. Meshberger FL. An interpretation of Michelangelo's Creation of Adam based on neuroanatomy. *JAMA*. 1990;264:1837-1841.
2. Eknoyan G. Michelangelo: art, anatomy, and the kidney. *Kidney Int.* 2000;57:1190-1201.
3. Barreto G, Oliveira MG. *The Secret Art of Michelangelo: A Lecture of Anatomy in the Sistine Chapel* [in Portuguese]. 4th ed. São Paulo (Brazil): Arx; 2004.
4. Mandelbrot BB. How long is the coast of Britain? Statistical self-similarity and fractional dimension. *Science.* 1967;156:636-638.
5. Mandelbrot BB. *The Fractal Geometry of Nature.* San Francisco, CA: W.H. Freeman; 1982.
6. Briggs J. *Fractals, the Patterns of Chaos.* New York, NY: Touchstone; 1992.
7. Sarnat HB, Netsky MG. *Evolution of the Nervous System.* 2nd ed. New York, NY, Oxford University Press; 1981.
8. Siler T. *Breaking the Mind Barrier: The Artscience of Neurocosmology.* New York, NY: Touchstone; 1992.